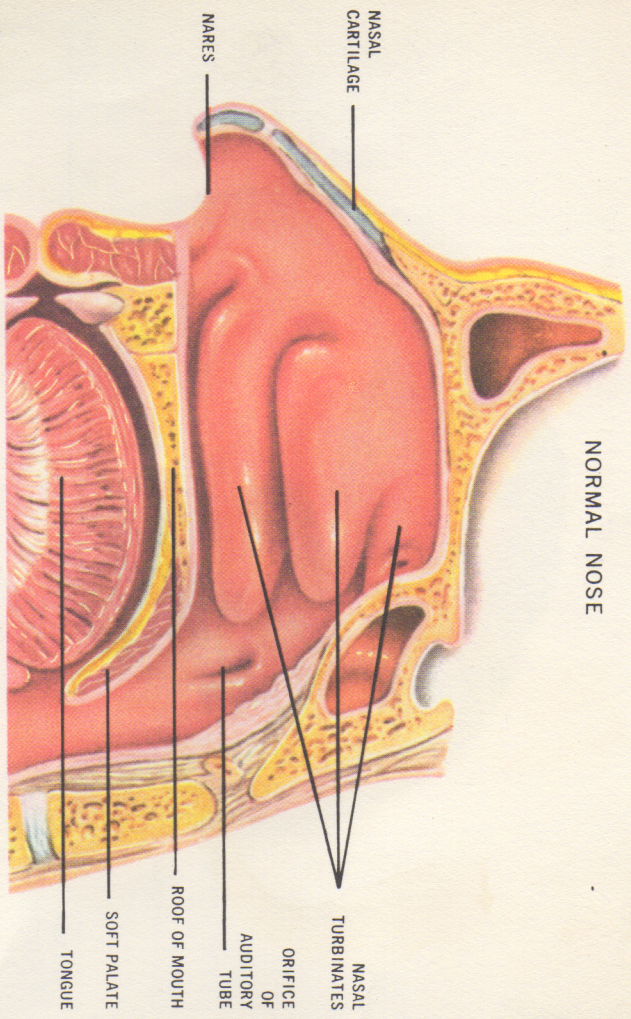


NORMAL NOSE



NASAL
CARTILAGE

NARES

NASAL
TURBINATES

ORIFICE
OF
AUDITORY
TUBE

ROOF OF MOUTH

SOFT PALATE

TONGUE